

# Efficient and fully automatic segmentation of the lungs in CT volumes

Yashin Dicente Cid  
yashin.dicente@hevs.ch

Oscar Alfonso Jiménez del Toro  
oscar.jimenez@hevs.ch

Adrien Depeursinge  
adrien.depeursinge@hevs.ch

Henning Müller  
henning.mueller@hevs.ch

University of Applied Sciences Western Switzerland  
University Hospitals and University of Geneva, Switzerland

## Abstract

The segmentation of lung volumes constitutes the first step for most computer-aided systems for lung diseases. CT (Computed Tomography) is the most common imaging technique used by these systems, so fast and accurate methods are needed to for allow early and reliable analysis. In this paper, an efficient and fully automatic method for the segmentation of the lung volumes in CT is presented. This method deals with the initial segmentation of the respiratory system, the posterior extraction of the air tracks, and the final identification of the tow lungs with 3 novel approaches. The system relies only on anatomical assumptions and was evaluated in the context of the VISCERAL Anatomy3 Challenge, achieving one of the best results.

## 1 Introduction

The first step of most computer-aided decision support systems for lung diseases is to segment the lungs. Moreover, an accurate segmentation of the two lungs can help the localization of other organs such as the liver or the heart that are closely related. X-ray computed tomography (CT) is considered to be the gold standard for pulmonary imaging. In the literature standard approaches for segmenting the respiratory system by thresholding the gray level images can be found in [IM03, HHR01, EBFFR02, LNC07]. The approaches are based on knowledge of the air gray-level in CT scans as CTs are based on tissue density. However, the gray range in the lungs regions can be affected by the radiation applied to acquire the CT and the possible change of the organ due to diseases (such as Fibrosis).

---

*Copyright © by the paper's authors. Copying permitted only for private and academic purposes.*

In: O. Goksel (ed.): Proceedings of the VISCERAL Anatomy Grand Challenge  
at the 2015 IEEE International Symposium on Biomedical Imaging (ISBI), New York, NY, Apr 16<sup>th</sup>, 2015  
published at <http://ceur-ws.org>

This work presents a novel and fully automatic approach for segmenting the lungs. We first apply a K–Means [Mac67] clustering of the CT intensities with a fixed number of clusters equal to 2 for segmenting the respiratory system. In the second step, the air tracks are removed from the initial segmentation. A novel technique is presented based on the mass–distribution of the lung volumes. The final step consist of identifying the right and left lung and refining the final mask by mathematical morphological operations in 3D. The separation of right and left lungs is challenging when both lungs seem to be connected. In this case, a bidirectional process across the 2D axial slices is applied. It allows to reduce the splitting error due to the information propagated between slices. Once both lungs are identified, a refinement in 3D is applied to each lung mask. The entire approach is completely unsupervised and provides an accurate and fast fully automatic segmentation of the lungs.

## 2 Database used

VISCERAL<sup>1</sup> Anatomy3 is the benchmark used in the VISCERAL Challenge at ISBI 2015. This benchmark contains a set of medical image series with annotated structures from various modalities. We evaluated our method for segmentation of right and left lung in the modalities of CT and with and without contrast agent (CTce). A total of 20 training patients in each modality were provided to optimize parameters.

The methods proposed by the participants were executed by the organizers of the challenge in the cloud and tested on a dataset of 10 patients per modality. The test set is not accessible by the participants to avoid possible overfitting of the methods. Despite the challenge offering a training set, the method proposed in this work was set up based on anatomical assumptions and no training was required. Patients from other datasets were used to define these assumptions, leaving the training set of this challenge for verification purposes.

## 3 Methods

The method presented is composed of three parts: an initial clustering of the CT values for segmenting the complete respiratory system (lungs, trachea and primary bronchi); a process to remove the trachea and primary bronchi; and finally, the identification of right and left lung with a refinement of each lung mask (see Fig. 1). Some steps of the process are performed in 2D following the axial dimension of the CT volume, i.e. going through the axial slices.

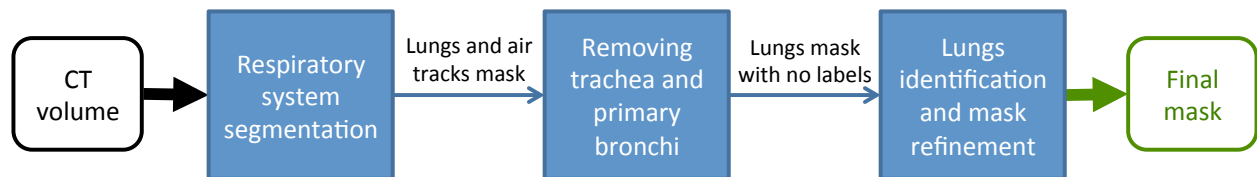

Figure 1: Pipeline of the proposed method for segmenting the lung volumes in CT.

### 3.1 Respiratory system segmentation

The proposed method for segmenting the respiratory system is based on the assumption that the latter is the biggest 3D connected air region inside the body. The first step is to fill the holes in the axial slices by a filling operation [Soi03], where a hole is defined as an area of dark pixels surrounded by lighter pixels. The resulting image contains a dense–body (see Fig. 2b). Then the absolute difference between the original and the dense–body image is computed. The resulting

<sup>1</sup><http://www.visceral.eu/>, as of 30 March 2015

image contains values that are clearly larger than 0 in the air regions inside the body, and close to 0 in the other regions (see Fig. 2c). In this new image, a K-Means [Mac67] algorithm with  $K = 2$  is performed, which yields a binary mask (see Fig.2d). Artificial objects in the CT containing air, such as the plastic bed, may be selected in the clustering, but are removed by analyzing the aspect ratio of the corresponding bounding boxes. Finally, the biggest connected 3D region is used as the initial lung mask. This region showed to include either both lungs connected by the trachea, or only one lung in the case of not being connected by the air track. To deal with this case, the process also selects all air blocks in the same axial slice-range, i.e., in the same slices where the largest 3D region is present and removes the regions that can not be easily connected to the lungs.

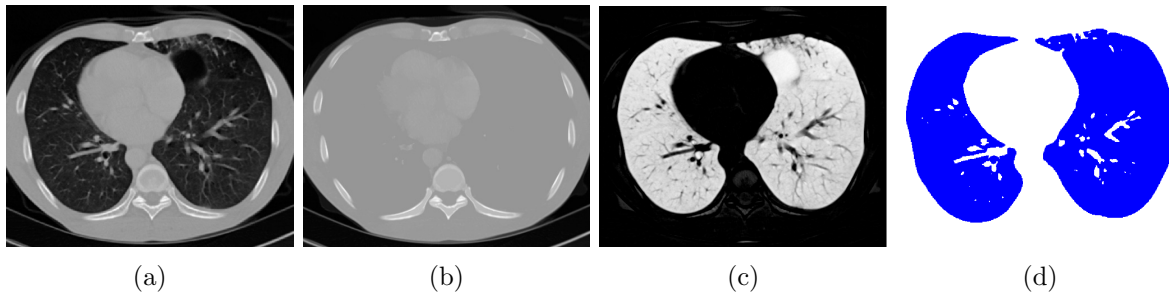


Figure 2: CT pre-processing and posterior clustering for segmenting the respiratory system inside the body. (a): Original CT. (b): Dense-body after filling holes. (c): Absolute difference between (a) and (b). (d): Mask achieved by 2-Means clustering over (c).

### 3.2 Removing trachea and primary bronchi

In order to remove the trachea and primary bronchi, the process defines a plane that divides the 3D image into two parts, leaving an equivalent number of mask-voxels on each side. This process uses the center of mass of the mask obtained in Section 3.1. The plane is used as the reference axis in each slice and the Euclidean distance from every pixel to this axis is computed (see Fig. 3a). Finally, each connected 2D component (CC) is assigned to the maximum distance found among all its constituting voxels (see Fig. 3b). The regions with a maximum distance to the central axis below a threshold are considered part of the air track and removed. This threshold is dynamically defined for each slice and patient according to the size of the mask.

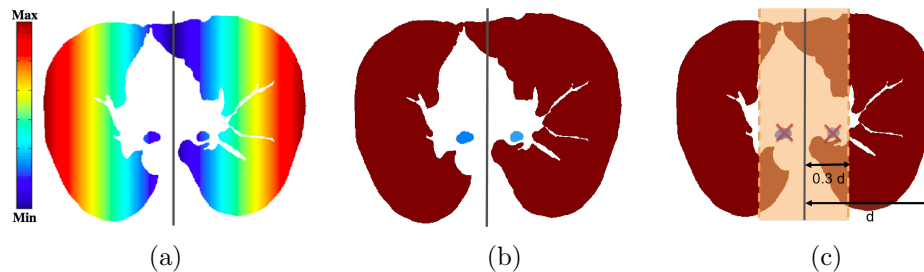


Figure 3: (a): Distance image to the reference axis (in gray). (b): Connected components labeled with the maximum distance found in their pixels. (c): Dynamic threshold to remove air tracks.

### 3.3 Right-left lung identification and mask refinement

After removing the trachea and the primary bronchi, two scenarios are present: either the lungs were already 3D-disconnected or they seemed to be merged by the parenchyma, resulting in a single

connected 3D component. An algorithm going through the sorted slices was designed to predict the best boundary in those slices where the lungs were connected. First, an initialization of the right (R) and left (L) labels is performed in the first slice presenting two significant CC. Then, the following slices with two CC (so-called 2-CC slices) are consistently labeled by projecting the labels from the previous slice. For the slices presenting only one CC (so-called, 1-CC slices) (see Fig. 4a), the algorithm applies a dilation on the labeled regions from the previous 2-CC slice, and projects them into the region of the current CC. The resulting labeled region contains pixels with one label (R or L), and with two labels (both R and L). This process propagates a boundary assumption to the current slice depending on the previous slice. This propagation results in a different labeling if the slices are selected in ascending or in descending order. Hence, the process is executed in both directions and the results are fused. The pixels with double label and the pixels with different label due to the double execution define a region of conflicts, as it is shown in Figure 4b. Then, a K-nearest neighbor algorithm [DHS01] in 3D is applied to decide the best label for each pixel of this region. Other small regions with no label after the procedure are labeled using the adjacent slices. Once both lungs are identified, the holes and the cavities are filled for each lung mask independently, achieving the result presented in Figure 4c.

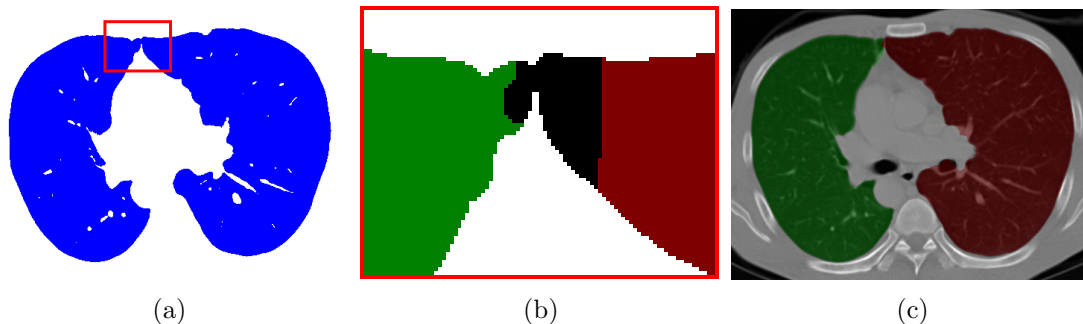


Figure 4: (a) Axial slice presenting only one connected component. The region in the red box shows where the two lungs are connected. (b) Detail of the merging zone in (a): In black, pixels with double label (R and L) due to the procedure explained in Section 3.3. (c) Final refined mask after identifying left and right lungs.

## 4 Results

The results shown in this section were provided by the organizers of the VISCERAL Grand Challenge at ISBI 2015. Table 1 shows a subset of the most relevant results. All results are published on the VISCERAL website. The evaluation was performed on the test set detailed in Section 2. The system presented in Section 3 showed to be one of the best algorithms presented in this edition, achieving a minimum Dice coefficient of 0.972 for both lungs in CT and CTce, and a maximum Hausdorff distance of 0.052.

## 5 Conclusions

The method presented in this paper introduces a new method for the extraction of the respiratory system in chest CT volumes. This initial step clearly separates the regions of interest, allowing to apply a fast K-Means clustering with a fixed number of 2 clusters. It detects the lung regions in a larger gray-level range than standard thresholding. Moreover, the extraction of the air tracks and the posterior differentiation of the lungs were done with simple geometric techniques that are computationally inexpensive. The procedures provide a fast system for segmenting the lungs in CT images that can be applied for large datasets. Furthermore, all steps rely on anatomical assumptions

Table 1: Table showing a subset of the performance measures provided by the VISCERAL Challenge. The best results for each modality and lung are highlighted in bold.

	Dice coefficient				Average Hausdorff distance			
	CT		CTce		CT		CTce	
	LL	RL	LL	RL	LL	RL	LL	RL
Our method	<b>0.972</b>	0.974	<b>0.974</b>	<b>0.973</b>	0.050	0.046	<b>0.050</b>	<b>0.052</b>
Participant 2	<b>0.972</b>	<b>0.975</b>	0.956	0.963	<b>0.043</b>	<b>0.038</b>	0.071	0.065
Participant 3	0.961	0.970	0.972	0.971	0.356	0.096	0.076	0.070
Participant 4	<b>0.972</b>	<b>0.975</b>	—	—	0.045	0.043	—	—
Participant 5	0.952	0.957	0.966	0.966	0.101	0.094	0.069	0.069

and require no training. The method showed almost perfect performance in CT and CTce. The presented segmentation can be applied directly to new CT scans with no further modifications. The participation in the VISCERAL challenge proved the reliability of this new efficient and fully automatic method, achieving an average Dice coefficient of 0.973 and an average Hausdorff distance of 0.0495.

## 6 Acknowledgments

This work was partly supported by the Swiss National Science Foundation in the PH4D project (grant agreement 320030–146804).

## References

- [DHS01] Richard O. Duda, Peter E. Hart, and David G. Stork. *Pattern Classification*. Wiley-Interscience, 2001.
- [EBFFR02] Ayman El-Baz, Aly A. Farag, Robert Falk, and Renato La Rocca. Detection, visualization, and identification of lung abnormalities in chest spiral CT scans: Phase I. In *Proceedings of the International Conf. on Biomedical Engineering*, Cairo, Egypt, 2002.
- [HHR01] Shiyong Hu, Eric A. Hoffman, and Joseph M. M. Reinhardt. Automatic lung segmentation for accurate quantitation of volumetric X-ray CT images. *IEEE Transactions on Medical Imaging*, 20(6):490–498, 2001.
- [IM03] S.G Armato III and H MacMahon. Automated lung segmentation and computer-aided diagnosis for thoracic {CT} scans. *International Congress Series*, 1256(0):977–982, 2003. {CARS} 2003. Computer Assisted Radiology and Surgery. Proceedings of the 17th International Congress and Exhibition.
- [LNC07] W. Li, S.D. Nie, and J.J. Cheng. A fast automatic method of lung segmentation in ct images using mathematical morphology. In *World Congress on Medical Physics and Biomedical Engineering 2006*, volume 14 of *IFMBE Proceedings*, pages 2419–2422. Springer Berlin Heidelberg, 2007.
- [Mac67] James MacQueen. Some methods for classification and analysis of multivariate observations. In *Proceedings of the fifth Berkeley Symposium on Mathematical Statistics and Probability*, volume 1, pages 281–297. University of California Press, 1967.
- [Soi03] Pierre Soille. *Morphological Image Analysis: Principles and Applications*, chapter 6. Springer, second edition edition, 2003.